Sprednja stran
Brezpogojna dostopnost
Tehnike Thompson: Anteriorni lumbalni dostop (z obrnjenim robom) Brau
Vstavljena slika: Rob z delovanjem na lateralno stran vretenčnega telesa stabilizira retrakcijo.
»Lopatice Thompson AL Brau so postale ključnega pomena za anteriorni mini-odprt dostop do lumbalne hrbtenice, saj imajo že 15 let tradicije na področju varnosti. Zaradi njih je razkritje stabilno in močno, torej omogočajo odlično vidljivost skozi ves postopek ne da bi bilo vmes treba opravljati kakršnekoli ponovne nastavitve in zapravljati čas za majhne popravke.«
- Salvador A. Brau, dr. med., FACS

Stran 2
TEHNIKE THOMPSON / BIOGRAFIJA + LASTNOSTI + MINI-DOSTOP
Salvador A. Brau, dr. med., FACS
Dr. Brau se je splošne vaskularne kirurgije izučil v bolnišnici Mount Sinai v New Yorku, kirurške posege z anteriornim dostopom na vseh nivojih hrbtenice pa opravlja že več kot 20 let. Izvedel je več kot 1500 odprtih anteriornih dostopov do lumbalne hrbtenice, je pa tudi pionir na področju anteriornega laparoskopskega in torakoskopskega dostopa. Dr. Brau, ki je sicer danes upokojen, je bil kot izredni klinični profesor kirurgije zaposlen na univerzi USC in v zdravstvenem centru Cedars-Sinai Medical Center v Los Angelesu.

Dr. Brau je razvil nov, »mini-odprt« anteriorni dostop k lumbalni hrbtenici. Oktobra leta 2000 je na vsakoletnem srečanju severnoameriškega društva za obolenja hrbtenice (North American Spine Society) v New Orleansu predstavil svoje izkušnje s tem dostopom na 386 primerih. Omenjeni poseg je odvisen od posebnih retraktorjev, ki jih je zasnoval dr. Brau. Ti retraktorji so bili patentirani 9. oktobra 2001, na voljo pa so le pri družbi Thompson Surgical Instruments, Inc.

Anteriorni dostop do lumbalne hrbtenice je zelo odvisen od tega, ali lahko kirurg, glede na poročanje o pojavnosti vaskularnih poškodb, razkritje doseže hitro in varno. Zahteva po »neposrednem« anteriorno-posteriornem razkritju za namen poravnave kletk in umetnih diskov je kirurgu predstavljala precejšen izziv, saj je moral narediti majhno zarezo, a kljub temu poskrbeti za ustrezno varnost, da ne bi prišlo do poškodb črevničnih žil in avtonomnega živčnega pleksusa. Pristop z uporabo retraktorskega sistema Thompson, ki je opisan v nadaljevanju, te skrbi močno omili.

Ekskluzivne lopatice z obrnjenim robom
Obrnjen rob z delovanjem na lateralno stran vretenčnega telesa stabilizira retrakcijo.

Brezpogojna dostopnost
Z radiotransparentnimi, anteriorno lumbalnimi lopaticami z obrnjenim robom je omogočeno zelo dobro razkritje anteriorno lumbalne hrbtenice, hkrati pa sistem preprečuje zdrse lopatic.

Močne radiotransparentne lopatice
Zaradi izjemne moči pri veliki retrakciji ne prihaja do prekomernega upogibanja. Lopatice so na voljo za globino do 250 mm, saj tako ustrezajo vsem velikostim bolnikov.

OPOMBA: Za podatke o naročanju glejte stran 7.

OPOMBA: Ker se nenehno trudimo ponuditi kar najboljše proizvode, so lahko nekatere slike v teh navodilih za uporabo videti malo drugače od dejanskih prejetih proizvodov.

TEHNIKE THOMPSON: ANTERIORNO LUMBALNO / SALVADOR A. DR. MED., BRAU, FACS
VPRAŠANJA IN DODATNE INFORMACIJE: +1 231 922 0177

Stran 3
Koraki za nastavitev retroperitonalnega mini-pristopa
Spodaj so predlagani koraki nastavitve za retroperitonalno anteriorno lumbalno razkritje, kot jih je opisal dr. Brau.

1. korak
Bolnik naj na rentgenski mizi leži na hrbtu.

Kirurg stoji na levi, asistent pa na desni strani. Nivo transverzne zareze na kraniokaudalni ravni je odvisen od nivoja hrbtenice, do katere dostopamo. Lateralni rentgen hrbtenice je nujen za določitev ustreznega mesta zareze.

POZOR: Če ima bolnik prekomerno telesno težo, pazite, da mu pri postavljanju prižeme na tirnice ne stiskate podlahtnega živca.

NASVET: Po potrebi uporabite večjo operacijsko mizo ali razširite obstoječo mizo za 68 cm z našim podaljškom tirnic (#41917).

2. korak
Leva mišica rektusa je mobilizirana cirkumferenčno. Po prvotni medialni retrakciji mišice rektusa, previdno zarežite 4 do 5 cm v posteriorni ovoj transverzalne fascije, vse dokler skozi ne vidite potrebušnice. Robove primite s hemostatom in jih dvignite stran ter previdno ločite od potrebušnice. Zarežite čim dlje inferiorno in superiorno. S kazalcem potrebušnico previdno potisnite posteriorno na robu fascialne incizije in počasi razvijte plast med njo in spodnjo površino interne poševne in transverzalne mišice ter fascijo. Na ta način boste prišli do retroperitonalnega prostora.

Previdno nadaljujte disekcijo s topim prstom v posteriorni smeri, nato pa začnite potiskati medialno, pri čemer poskušajte dvigniti potrebušnico stran od mišice psoas. Pazite, da na tej točki ne prodrete v retropsoas, saj bi to vodilo v nepotrebno krvavitev v slepo vrečo. Genitofemoralni živec zlahka prepoznate čez psoas. Sečevod lahko ponavadi prepoznate, ko potrebušnico dvignete stran od psoasa. Pri obeh strukturah je treba paziti, da ju ne poškodujete.

Vstavljena slika: Začetek retroperitonalne disekcije lateralno od mišice rektus

OBIŠČITE NAS NA SPLETU: THOMPSONSURGICAL.COM

Stran 4
TEHNIKE THOMPSON / NAMESTITEV RETRAKTORSKE LOPATICE
Koraki za nastavitev retroperitonalnega mini-pristopa (nadaljevanje)

3. korak
Ko identificirate psoas, zatipajte medialno, dokler ne najdete diska, vretenčnega telesa in črevnične arterije. Če velikost zareze to dopušča, nato vstavite celotno dlan in v retroperitonalnem območju napravite pest. S stisnjeno pestjo zanihajte navzgor in navzdol ter tako potrebušnico dvignite stran v vse smeri. Nadaljujte s topo disekcijo ter razkrijte celo dolžino skupne in zunanje črevnične arterije čim dalj distalno, nato pa previdno začnite s topo disekcijo ob lateralnem robu arterije. Tako boste razkrili levo skupno črevnično veno tik pod arterijo. Z disekcijo nadaljujte posteriorno in tako identificirajte iliolumbalno veno/-e. Variacije pri sestavi skupne črevnične vene in lumbalnih ven so pogoste, zato morate biti zelo pozorni, da pravilno identificirate, zavežete in opravite transekcijo teh žil ter se izognete avulziji. Zdaj lahko levo črevnično veno in arterijo ločite od hrbtenice z nežno gobico v obliki arašida, konico prsta in topo povzdigovalno disekcijo.

Vstavljena slika: Nadaljevanje retroperitonalnega pristopa

4. korak
Drsno prižemo Elite II Rail Clamp pritrdite na tirnico mize čez sterilno pokritje na tisti strani, kjer bo manj ovirala kirurga (A). Prečnico vstavite v zglob in namestite v položaj 2 cm nad mestom posega (B).

5. korak
Vse vaskularne strukture nato potisnite z leve proti desni, kar omogoča ustrezen pregled disk/-ov in vretenčnih teles, ki so del posega. Segmentalne žile, ki potekajo čez vdolbine na anteriorni površini teles, lahko prerežete med sponkami in s topo disekcijo potisnete na stran. Poskrbite, da lahko med veno in vez vstavite vsaj en prst, da lahko desni lateralni rob hrbtenice zatipate tako, da so žile nad vašim prstom oziroma vašimi prsti.

Vstavljena slika: Disekcija s prstom pod žilami po ligaturo iliolumbalne vene

TEHNIKE THOMPSON: ANTERIORNO LUMBALNO / SALVADOR A. DR. MED., BRAU, FACS
VPRAŠANJA IN DODATNE INFORMACIJE: +1 231 922 0177

Stran 5
Koraki za nastavitev retroperitonalnega mini-pristopa (nadaljevanje)

6. korak
Lateralne podaljševalne roke pritrdite na prečnico (A) in postavite tik nad horizont bolnika (B).

7. korak
Kirurg z levo roko nato znova vstopi v retroperitonalni prostor, kjer je rektus zdaj premaknjen lateralno, nato pa s prsti najde pot do desne strani hrbtenice. Radiotransparentno lopatico z obrnjenim robom za anteriorni dostop do hrbtenice nato slepo namesti na desno stran hrbtenice, pri čemer kot vodilo uporablja prst/-e.

Vstavljena slika: Prvotna vstavitev lopatice z obrnjenim robom na desno stran hrbtenice

8. korak
Lopatico je nato treba pritrditi na lateralne podaljševalne roke retraktorskega ogrodja, pri čemer je treba dvigniti vaskularne strukture in razkriti anteriorno površino hrbtenice. Ko je lopatica z obrnjenim robom enkrat pritrjena na retraktor Thompson, se ne bo več premikala. Zaradi obrnjenega roba je lopatica zasidrana na rob hrbtenice, hkrati pa obrnjen rob po začetku pritiskanja lopatici tudi preprečuje, da bi zdrsnila anteriorno. Brez obrnjenega roba retraktorska lopatica ne bi učinkovito delovala.

9. korak
Ker je rektus zdaj lateralno umaknjen, bo pri potiskanju retraktorske lopatice za razkritje hrbtenice v neposrednem anteroposteriornem pogledu precej manj upora, več pa bo tudi prostora za namestitev ovitkov za pomoč pri vstavljanju navojnih pripomočkov, stegenskega obročka ali umetnega diska. Drugo lopatico z obrnjenim robom namestite na levo stran hrbtenice in jo pritrdite na ogrodje Thompson. Pogosto je za dokončanje razkritja treba superiorno in inferiorno namestiti dodatne retraktorske lopatice. Ko so lopatice dobro pritrjene na lateralno steno hrbtenice, lahko kirurg hrbtenice in asistent prosto operirata na disku ne da bi jima bile v napoto dodatne roke ali retraktorji, in s precejšnjim prepričanjem, da žile ne bodo uhajale iz retraktorjev in s tem izpostavljene poškodbam.

Vstavljena slika: Obe lopatici z obrnjenim robom nameščeni in delujoči na lateralni strani diska in vretenčnega telesa

OBIŠČITE NAS NA SPLETU: THOMPSONSURGICAL.COM

Strani 6 + 7
TEHNIKE THOMPSON / ANTERIORNI LUMBALNI SISTEM + DODATNI PRIPOMOČKI
PODATKI O NAROČANJU

Zadnja stran
Legenda simbolov:
Proizvajalec Pooblaščeni zastopnik v EU Oznaka CE Opozorila/previdnostni ukrepi Nesterilno

Thompson Retractor

Uncompromised Exposure™

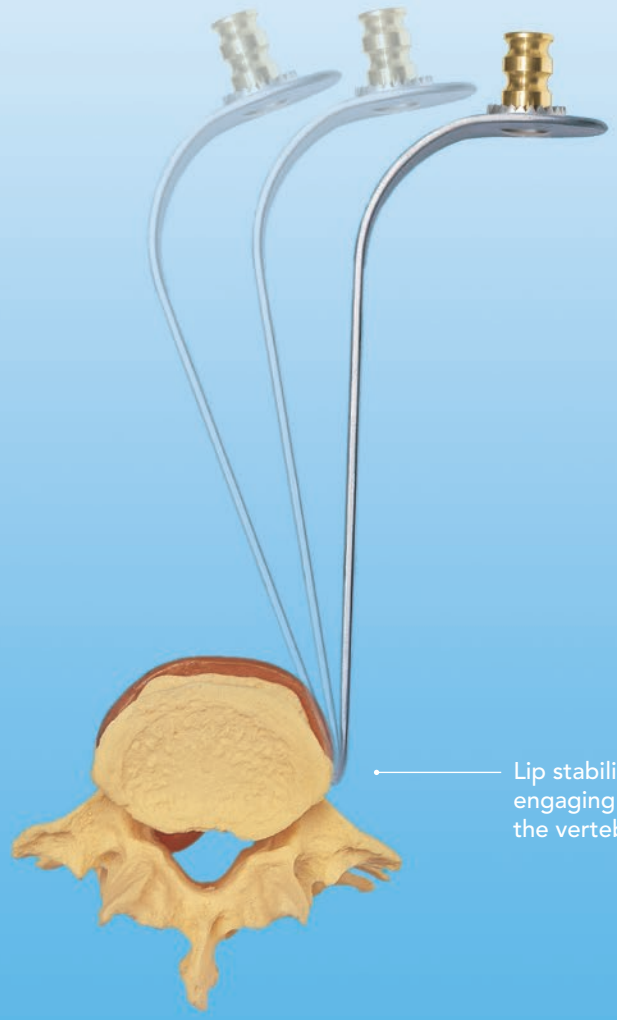

Thompson Techniques:

BRAU (REVERSE LIP) ANTERIOR LUMBAR ACCESS

"The Thompson AL Brau Blades have become essential for the Anterior Mini-Open approach to the lumbar spine with a proven 15 year track record of safety. You get steady, rock solid exposure providing excellent visualization throughout without the need to re-adjust thus saving time by reducing the 'fiddle factor.'"

- Salvador A. Brau, MD, FACS

Salvador A. Brau, MD, FACS

Dr. Brau trained in general vascular surgery at the Mount Sinai Hospital in New York City and has been performing anterior access procedures to all levels of the spine for over 20 years. He has performed over 1,500 open anterior approaches to the lumbar spine and has also been a pioneer in anterior laparoscopic and thoracoscopic access. Now retired, Dr. Brau was Assistant Clinical Professor of Surgery at USC, and worked at Cedars-Sinai Medical Center in Los Angeles.

Dr. Brau has developed a new "mini-open" anterior approach to the lumbar spine. In October of 2000, he presented his experience with this approach in 386 cases, along with a video of the procedure, to the North American Spine Society Annual Meeting in New Orleans. This procedure is dependent on special retractors designed by Dr. Brau. These retractors received a patent on October 9, 2001, and are available exclusively from Thompson Surgical Instruments, Inc.

The anterior approach to the lumbar spine is heavily dependent on the ability of the access surgeon to provide exposure quickly and safely in view of a reported incidence of vascular injury. The requirement of a "straight on" anterior-posterior exposure for alignment of cages and artificial discs has presented a significant challenge for the approach surgeon to provide a small incision and yet maintain the degree of safety necessary to prevent injury to the iliac vessels and autonomic nerve plexus. The approach described here utilizing the Thompson retractor system significantly reduces these concerns.

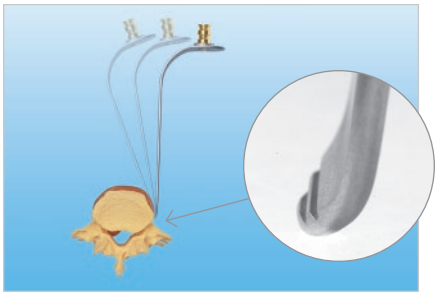

Exclusive Reverse Lip Blades

Reverse lip stabilizes retraction by engaging the lateral aspect of the vertebral body.

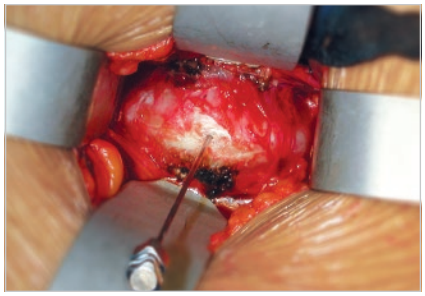

Uncompromised Exposure

Radiolucent Reverse Lip Anterior Lumbar blades offer phenomenal exposure of the anterior lumbar spine and prevent blade slippage.

Radiolucent, Strong Blades

Superior strength prevents excessive flexing under heavy retraction. Available up to 250mm deep to accommodate all patient sizes.

NOTE
See page 7 for ordering information.

NOTE
As we continually strive to provide the best products possible, some of the images in this user manual may appear slightly different from the product received.

Retroperitoneal Mini-Approach Set Up Steps

Below are the suggested set up steps for retroperitoneal anterior lumbar exposure, as outlined by Dr. Brau.

Step 1

Place the patient in the supine position on an x-ray table.

The approach surgeon stands on the left and the assistant on the right. The level of the transverse incision in the craniocaudad plane depends on the level of the spine to be approached. A lateral x-ray of the spine is essential to determine the proper placement of this incision.

CAUTION
If the patient is obese, avoid compressing the ulnar nerve when placing rail clamp.

TIP
When necessary, use a wider OR table or add 2 ¼" to the width of the table by using our Rail Extender (#41917).

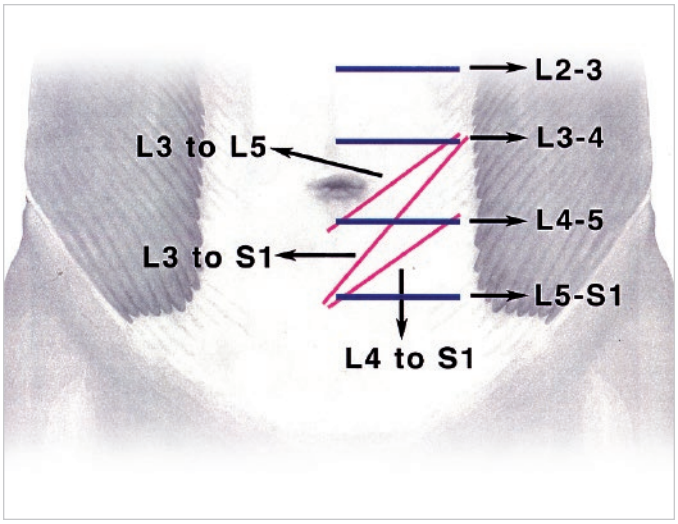

Step 2

The left rectus muscle is mobilized circumferentially. With the rectus muscle initially retracted medially, carefully incise the posterior sheath of transversalis fascia 4 to 5 cm until the peritoneum is seen to shine through. Grasp the edges with a hemostat and lift it away and very carefully dissect if from the peritoneum. Incise it as far inferiorly and superiorly as possible. Using your index finger, carefully push the peritoneum posteriorly at the edge of the fascial incision and slowly develop a plane between it and the undersurface of the internal oblique and transversus muscles and fascia. This will lead you to the retroperitoneal space.

Continue careful blunt finger dissection posteriorly, and then start pushing medially trying to elevate the peritoneum away from the psoas muscle. Be careful not to enter the retropsoas space at this point, as this will lead to unnecessary bleeding in a blind pouch. The genitofemoral nerve can be easily identified over the psoas. The ureter can usually be identified as the peritoneum is lifted away from the psoas. Both of these structures should be preserved from injury.

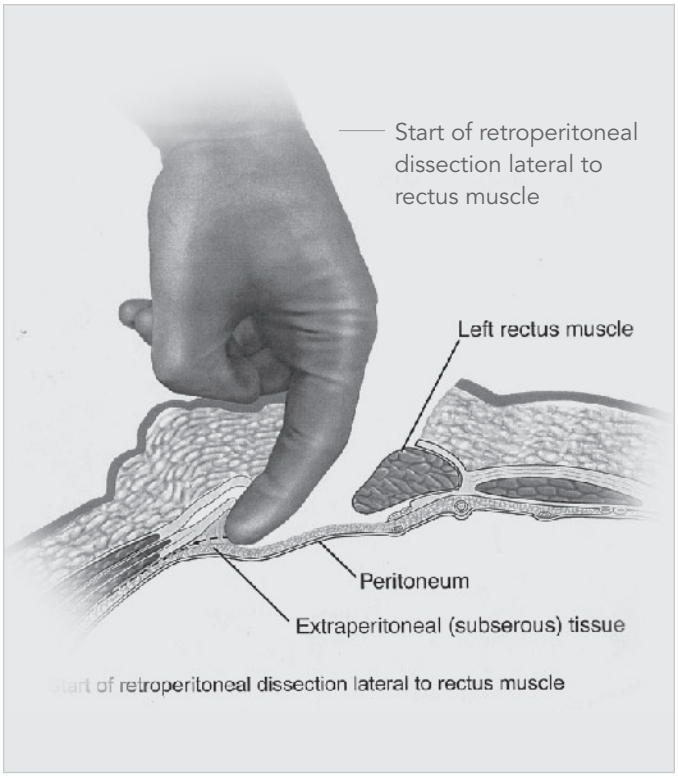

Retroperitoneal Mini-Approach Set Up Steps *(continued)*

Step 3

Once the psoas is identified, palpate medially to feel for the disc and vertebral body and iliac artery. At this point, if size of the incision allows, insert the entire hand and make a fist in the retroperitoneal area. Sweep with the closed fist up and down to elevate the peritoneum away in all directions. Continue with blunt dissection to expose the entire length of the common and external iliac arteries as far distally as possible, and then start careful blunt dissection along the lateral edge of the artery. This will expose the left common iliac vein just underneath the artery. Continue the dissection posteriorly to identify the ileolumbar vein(s). Variations in the formation of the common iliac vein and the lumbar veins are common, and great care must be exercised in order to identify, ligate and transect these veins and avoid avulsion. The left iliac vein and artery can now be separated away from the spine using gentle, peanut sponge, fingertip and blunt elevator dissection.

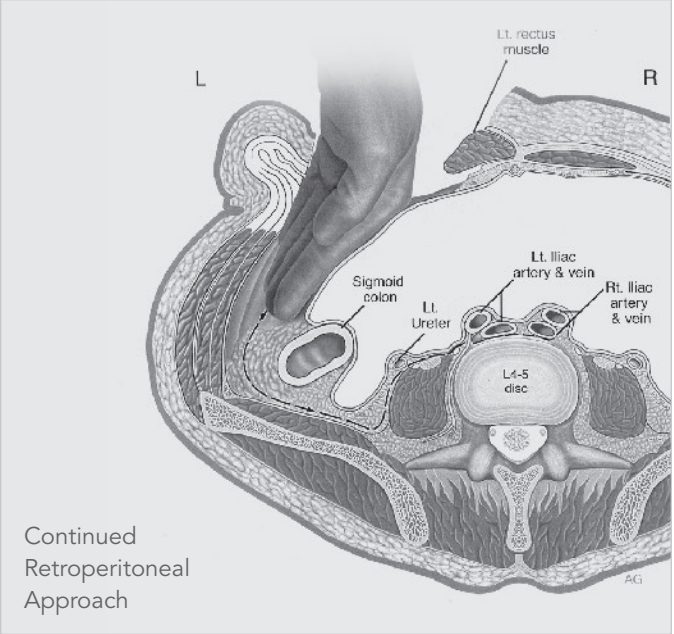

Continued Retroperitoneal Approach

Step 4

Secure the Elite II Rail Clamp to the table rail over the sterile drape on either side of the table, whichever side keeps the surgeon's operating field clear (A). The Crossbar is inserted into the joint and positioned 2 cm above the operative site (B).

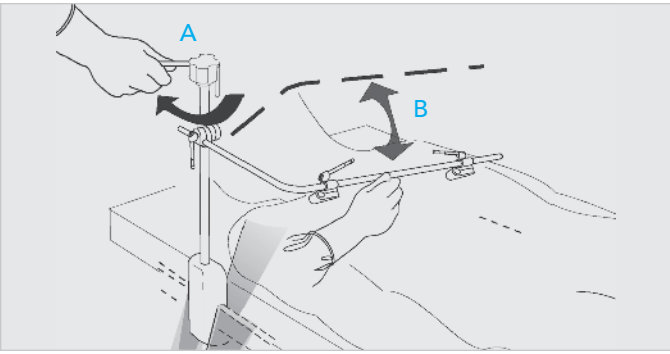

Step 5

All vascular structures are then swept from the left to right, providing adequate visualization of the disc(s) and vertebral bodies involved. Segmental vessels running across the valleys on the anterior surface of the bodies can be transected between clips and swept to the sides with blunt dissection. Make sure you can get at least one finger between the vein and the ligament so that you can palpate the right lateral edge of the spine with the vessels above your finger(s).

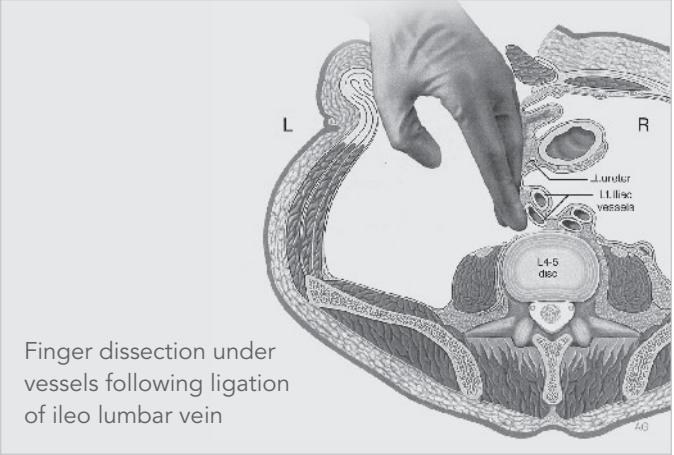

Finger dissection under vessels following ligation of ileo lumbar vein

Retroperitoneal Mini-Approach Set Up Steps *(continued)*

Step 6

The lateral extension arms are attached to the crossbar (A) and positioned just above the horizon of the patient (B).

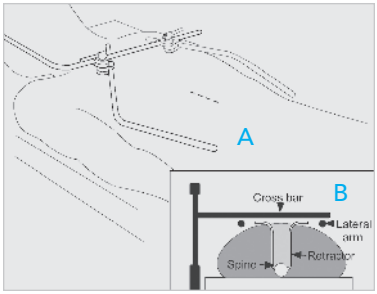

Step 7

The surgeon's left hand then re-enters the retroperitoneal space with the rectus now moved laterally, and the fingers find their way to the right side of the spine. A Radiolucent Reverse Lip Anterior Spine Access blade is placed blindly on the right side of the spine using the finger(s) as a guide.

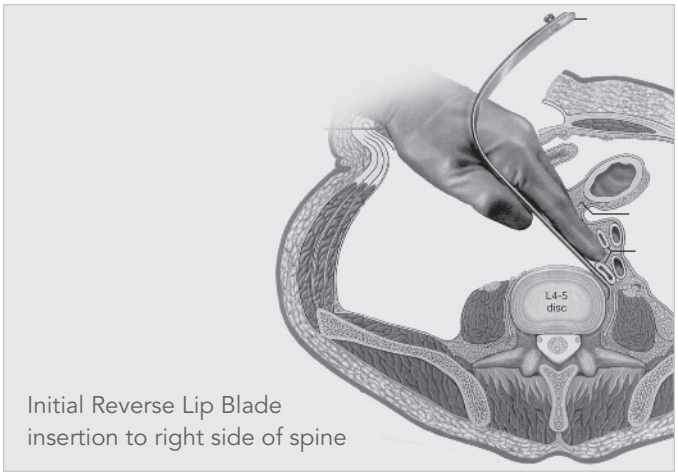

Initial Reverse Lip Blade insertion to right side of spine

Step 8

This blade is then attached to the lateral extension arms of the retractor frame, elevating the vascular structures and exposing the anterior surface of the spine.

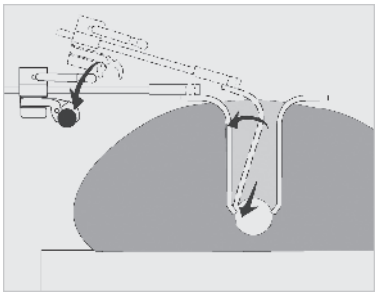

Once secured to the Thompson Retractor, the reverse-lipped blade will not move. The reverse lip keeps the blade anchored to the edge of the spine and prevents it from slipping anteriorly once tension is applied. Without this reverse lip, the retractor blade will not work effectively.

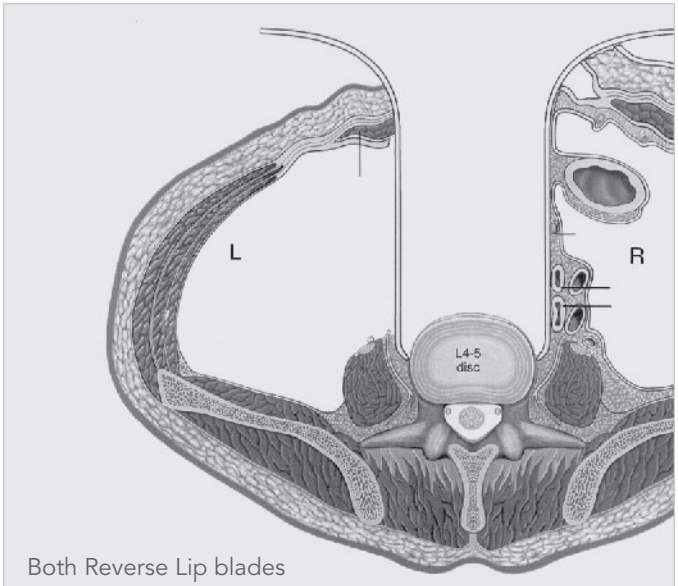

Both Reverse Lip blades deployed and engaged at lateral aspect of disc and vertebral body

Step 9

With the rectus now retracted laterally, there will be much less resistance when pushing the retractor blade to expose the spine in a direct AP view and allow placement of the sleeves for insertion of a threaded device, femoral ring or artificial disk. Place a second reverse-lip blade on the left side of the spine and attach to the Thompson frame. Commonly, additional retractor blades need to be placed superiorly and/or inferiorly to complete the exposure. With the blades well anchored to the lateral wall of the vertebral column, the spine surgeon and the assistant can now work on the disc without other hands or retractors being in the way and with relative security that vessels will not move around the retractors and expose themselves to injury.

Anterior Lumbar System Components



ANTERIOR LUMBAR SYSTEM #SL82019

REF	QTY	ITEM DESCRIPTION	PART #
A	1	Elite III Rail Clamp with 1 Cam Joint 16"	43902ACL
B	1	Crossbar with 2 Cam III Joints 24"	43900BC
C	2	20" Angled Arm (10" x 10") @ 45°	44120
D	2	24" Angled Arm (8" x 16") @ 45°	44124N
E	5	Cam II Clip-on Quick Angle 8"	SL42126WGP
F	1	Micro-Adjustable II Clip-on Quick Angle 10"	SL45006CGP
G	2	T-Handle	60020
H	1	Quick Angle Hand Held Adapter	SL42128G
I	1	Suction for Anterior Lumbar Surgery	51234
J	1	Anterior Lumbar Depth Gauge 335mm	51236
	2	Radio. Malleable Renal Vein 25mm x 140mm	SL46119BET
K	2	Radio. Malleable Renal Vein 25mm x 190mm	SL46119CET
L	2	Radio. Malleable 51mm x 203mm (2" x 8")	SL46122ET
M	1	Radio. Harrington 64mm x 152mm (2 ½" x 6")	SL46160ET
N	1	Radio. Splanchnich 51mm x 115mm (2" x 4 ½")	SL46145ET
O	2	Radio. Balfour 65mm x 72mm (2 ½" x 2 ¾")	SL46140ET
	4	Radio. Concave 25mm x 100mm (1" x 4")	SL46560
	4	Radio. Concave 25mm x 120mm (1" x 4 ¾")	SL46562
P	4	Radio. Concave 25mm x 140mm (1" x 5 ½")	SL46564
	4	Radio. Concave 25mm x 160mm (1" x 6 ¼")	SL46566

REF	QTY	ITEM DESCRIPTION	PART #
	4	Radio. Concave 25mm x 180mm (1" x 7")	SL46568
Q	2	Reverse Lip Malleable 25mm x 200mm	SL46192ET
	2	Reverse Lip Malleable 32mm x 200mm	SL46193ET
	2	Reverse Lip Tapered 25mm x 100mm	SL46260TET
R	2	Reverse Lip Tapered 25mm x 150mm	SL46265TET
	2	Reverse Lip Tapered 25mm x 200mm	SL46270TET
	2	Reverse Lip Rigid 25mm x 110mm	SL46261RET
	2	Reverse Lip Rigid 25mm x 130mm	SL46263RET
S	2	Reverse Lip Rigid 25mm x 150mm	SL46265RET
	2	Reverse Lip Rigid 25mm x 170mm	SL46267RET
	2	Reverse Lip Rigid 25mm x 190mm	SL46269RET
	2	Reverse Lip Rigid 32mm x 120mm	SL46282RET
T	2	Reverse Lip Rigid 32mm x 140mm	SL46284RET
	2	Reverse Lip Rigid 32mm x 160mm	SL46286RET
	2	Reverse Lip Rigid 32mm x 180mm	SL46288RET
	2	Reverse Lip Rigid 32mm x 200mm	SL46290RET
	1	Instrument Case	50000G
	1	Instrument Case - Exp. Reverse Lip ASA	50000ERL
	1	Instrument Case - AL Renal Vein Blades	50000ALR
	1	Instrument Case - Anterior Lumbar	50000ALT

SYSTEM NOTICE:
Non-S-Lock system available, but may require a longer lead time.
Please call for more information.

Table Adapters + Rail Extenders

Providing stable support on the OR table for the table mounted frame

When bedrail space is not available for a rail clamp, or, when the bedrail needs to be offset to accommodate obese patients, a rail adapter or rail extender should be applied.

TABLE ADAPTER

Easily connects to Jackson Spine tables to add a standard bed rail for applying a table mounted Thompson Retractor System to your operation.

REF	ITEM DESCRIPTION	PART #
U	Jackson Spine Frame Adapter	41927



RAIL EXTENDERS

Apply a Rail Extender to your OR table to increase your rail length or width and provide more attachment options for Thompson rail clamps.

REF	ITEM DESCRIPTION	PART #
V	Rail Extender 15" Single Clamp	5844
	Rail Extender 20" Single Clamp	41938
W	Rail Extender 14" Long with 2 ¼" Offset Dual Clamp	41917
	Rail Extender 22" Dual Clamp	41929

For a Free Trial Call Today*

1.800.227.7543

Rev E
041619
ttbrau

Uncompromised Exposure

VISIT US ONLINE: **THOMPSONSURGICAL.COM**

Thompson SURGICAL INSTRUMENTS
10341 East Cherry Bend Road
Traverse City, Michigan 49684
phone: 231.922.0177
fax: 231.922.0174
thompsonsurgical.com

EC REP **Emergo Europe**
Prinsessegracht 20
2514 AP The Hague
THE NETHERLANDS

* Free trial valid for U.S. customers only. Customers outside U.S. please call +1-231-922-0177 for availability.

Patents: US4971038, US5025780, US5888197, US5897087, US5902233, US5984865, US6033363, US6416465, US6511423, US7338442, US7749163, US8257255, US8360971, US8617064, US9872675
Other patents pending.

CE 0297

Made In USA

Symbol Legend:

Manufacturer	Authorized EC Rep	CE Mark	Warnings / Precautions	Non-Sterile